Primary sclerosing cholangitis
and
challenges in diagnosis and treatment

Dr Ramin Niknam
MD, MPH
Professor of gastroenterology and Hepatology
2024

Introduction

- PSC is a chronic autoimmune cholestasis
- PSC is progressive with10-y survival 65%
- Symptoms include fatigue, abdominal pain, fever, and pruritus and/or cirrhosis and malignancy complications
- Challenges about pathophysiology, diagnosis, and treatment

Diagnosis

- Sonography is nondiagnostic
- CT is limited in assessment
- Normal US or CT can not rule out PSC
- 3D MRI/MRCP with T1w and T2w axial images and contrast should be obtained
- Re-MRI/MRCP in 1 year if unclear diagnosis
- Exclusion of secondary cholangitis

PSC differential diagnosis

Cholangiocarcinoma (CCA)

Diffuse intrahepatic metastasis

Ischemic cholangitis

IgG4-associated cholangitis (IAC)

Recurrent pyogenic cholangitis

Sclerosing cholangitis in critical illness

Choledocolithiasis

AIDS cholangiopathy

Sarcoidosis

Portal hypertensive biliopathy (choledochal varices)

Congenital (choledochal cysts, biliary atresia)

Chronic biliary infestation (liver fluke or ascaris)

Surgical biliary trauma

Cystic fibrosis

Eosinophilic cholangitis

Histiocytosis X

Mast cell cholangiopathy

Sclerosing cholangitis in critically ill patients

Diagnosis

- ERCP should be avoided for diagnosis
- IgG4 levels should be measured
- Liver biopsy for suspected small-duct PSC or AIH overlap or other differential diagnosis
- Small-duct PSC diagnosis is difficult (normal MRI/MRCP but positive PSC biopsy)
- Small-duct PSC should be monitored by MRI/MRCP every 3–5 y

Treatment

- No definite treatment
- Clinical trials should be considered
- UDCA 10-15 mg/kg/day
- Pruritus: heat avoidance, emollients, and antihistamines, UDCA
- Alternatives for refractory pruritus include sertraline 100 mg/d, naltrexone titrated to a dose of 50–100 mg/d, and rifampin 150–300 mg/BID

Treatment

- Antibiotics should be used for cholangitis
- ERCP for cholangitis nonresponsive to antibiotics
- Oral vancomycin (insufficient evidence)
- Concurrent AIH should be treated
- Gallbladder polyps ≤ 8mm may be monitored with US every 6 months
- Cholecystectomy may be considered for gallbladder polyps >8 mm

Screening

- Ileocolonoscopy at 5-y intervals
- Varices & HCC screening in cirrhosis
- CCA and gallbladder carcinoma surveillance annually by MRI/ MRCP and serum CA 19-9
- Surveillance is not recommended for small-duct or age <18-y
- Bone densitometry at 2-3-y intervals
- Nutritional assessments yearly

ERCP in PSC

- New-onset or worsening pruritus,
- Weight loss with unknown cause
- Worsening serum liver test abnormalities,
- Increasing CA 19-9
- Recurrent bacterial cholangitis
- Progressive bile duct dilation
- Relevant strictures (CBD or hepatic ducts stricture associated with cholestasis symptoms)

ERCP in PSC

- Post-ERCP complications is considerable
- ERCP should be avoided for diagnosis
- MRI/MRCP should be considered prior to ERCP
- Antimicrobial prophylaxis use pre-and- post ERCP
- ERCP technique by endoscopist’s decision

Liver Tx in PSC

- Cirrhosis complications
- Recurrent cholangitis
- Intractable pruritus
- Early-stage hepatobiliary cancers
- Post-Tx elevated liver enzymes should undergo Bx & MRCP for diagnosis of recurrent-PSC vs. rejection vs. biliary complications

Cholangiocarcinoma in PSC

- Increased incidence of CCA in PSC
- CCA most commonly occurs ages of 30-45 y before cirrhosis
- Challenges of diagnosis and therapy of CCA



Taylor & Francis
Taylor & Francis Group

Expert Review of Gastroenterology & Hepatology

ISSN: 1747-4124 (Print) 1747-4132 (Online) Journal homepage: http://www.tandfonline.com/loi/ierh20

Diagnosis of cholangiocarcinoma in primary sclerosing cholangitis

Cholangiocarcinoma in PSC



Taylor & Francis
Taylor & Francis Group

Expert Review of Gastroenterology & Hepatology

ISSN: 1747-4124 (Print) 1747-4132 (Online) Journal homepage: http://www.tandfonline.com/loi/ierh20

Diagnosis of cholangiocarcinoma in primary sclerosing cholangitis

Diagnosis of CCC in PSC

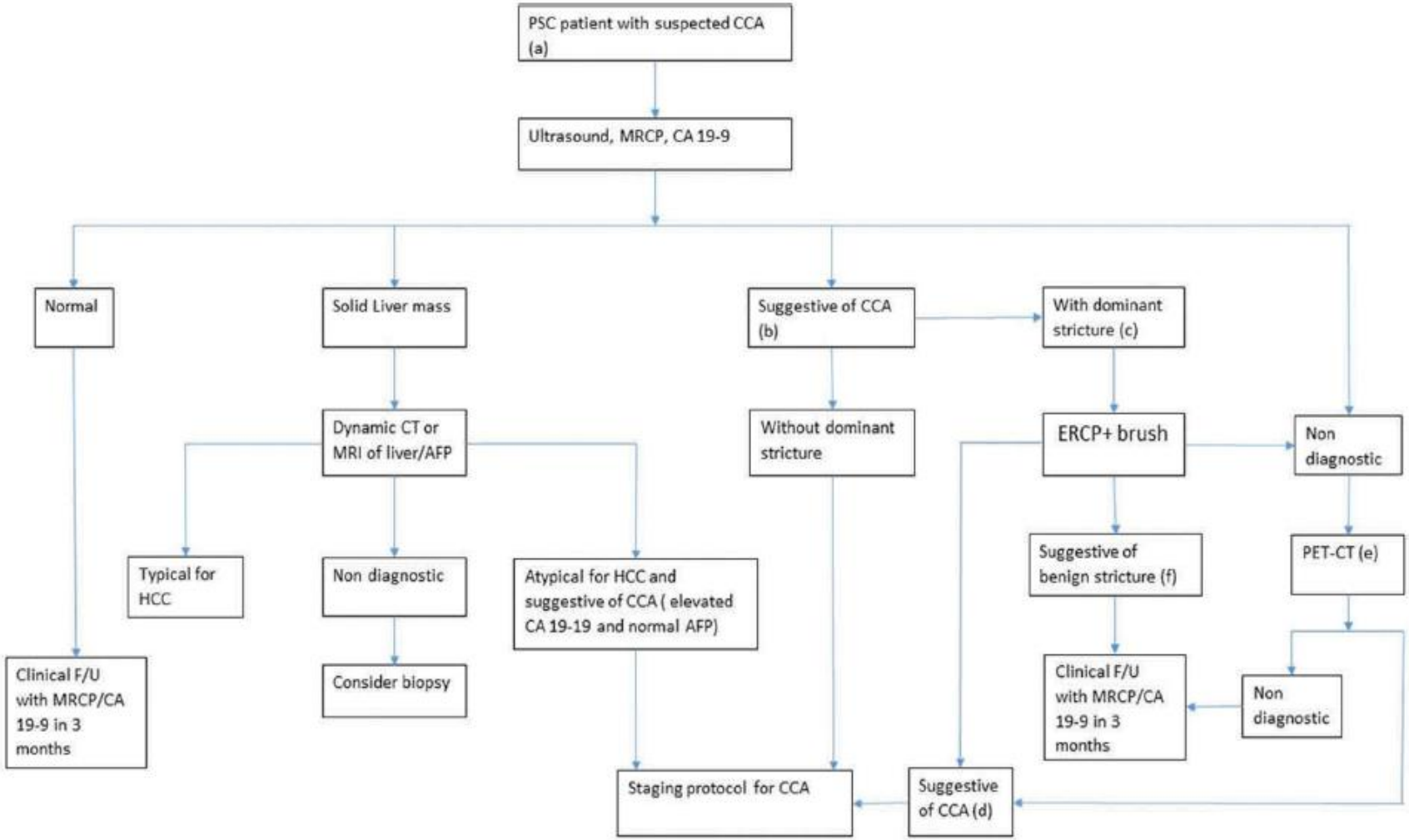

Therapy of CCC in PSC

- CCA should be referred to expert center
- Surgery is treatment of choice if possible
- Biliary drainage by ERCP or PTBD may be
- Adjuvant capecitabine
- LT only be considered under research protocols (EUS FNA or percutaneous biopsy can not be performed if LT is an option)



- PSC remains a poorly understood disease
- Normal US or CT can not rule out PSC
- Diagnosis of small-duct PSC is difficult
- No definite medical therapy
- Liver Tx should be discussed in Tx clinic
- Challenges of diagnosing and therapy of CCA
- Clinical trial is recommended


QUESTIONS? COMMENTS?